



PATIENT

Bijou Mueller

SPECIES

Feline

BREED

DSH

SEX

Female Spayed

AGE

20 years

WEIGHT

7.4lbs

INTERPRETED BY

Maggie Machen Lamy,
DVM, DACVIM
(Cardiology)

IMAGING PERFORMED BY

Jessica Miller, RDMS

HOSPITAL NAME

Animal General on
Hudson

REFERRING VET

Dr. Ng

INVOICE

32105

DATE

8/2/23

PRESENTING CLINICAL SIGNS

History: New grade 2/6 systolic murmur. History of hypertension, CRD, +/- intestinal neoplasia vs IBD. Picky appetite.

-Current meds: Amlodipine, lactulose, pred, subq 100cc 1x week

-Abnormal PE/Chem/CBC/UA Results: BUN 42, Cre 1.1, SDMA 15, Leukocytosis, WBC 25.3, Anemia, RBC 5.1, HCT 26

ECHOCARDIOGRAM FINDINGS

2D, m-mode, color flow and doppler imaging is available. The left ventricular wall is normal in dimension. There is a diffusely hyperechoic endocardium consistent with fibrosis. The endocardium also appears mildly remodeled. The papillary muscles appear mildly remodeled. The left atrium is normal in size. The right atrium is normal in size. The right ventricle appears normal. The tricuspid valve appears normal in structure and mobility. Trace tricuspid regurgitation. The mitral valve is normal in structure and mobility. Trace mitral regurgitation. Blood flow through the RVOT is mildly elevated in velocity based upon Doppler and color flow, likely secondary to tachycardia creating a benign outflow tract obstruction. Blood flow through the LVOT appears normal with no evidence of obstruction. No evidence of cardiac tumors or metastatic lesions on this scan.

CARDIAC CHART

FELINE CARDIAC PARAMETERS	BODY WEIGHT (kg)	HR (BPM)	IVSd (cm) <small>(Moise, Pipers)</small>	LVIDd (cm) <small>(Moise, Pipers)</small>	LVWd (cm) <small>(Moise, Pipers)</small>	FS (%)	EF (%)
NORMAL PARAMETER	-----	150-240	0.35-0.55	<2 (mean 1.5)	3.5-0.55	35-67	80-100
PATIENT	3.4	220	0.46	1.5	0.45	48	82
FELINE CARDIAC PARAMETERS	LA/AO (Boon)	LA/AO HEART BASE (Swe) <small>(Abbott)</small>	LA 2D short axis Base view (cm) <small>(Abbott)</small>	LVOT VEL (m/s)	RVOT VEL (m/s)	E max (m/s)	
NORMAL	<1.5	<1.3	<1.2	<1.6	<1.3	<0.9	
PATIENT	1.3	1.3	1.2	1.5	1.9	NM	

*Note: All measurements based upon multi-modal images and methods. An average value is reported.

Adapted from June Boon, Veterinary Echocardiography, 1998

Abbott J & MacLean H JVIM 2006;20: 111-119, Moise et al. Am J Vet Res 47:1476, 1986. Pipers et al. Am J Vet Res 40:882, 1979.

INTERPRETATION OF THE FINDINGS & FURTHER RECOMMENDATIONS

The only cause of a murmur identified is a heart rate dependent flow obstruction through the right ventricle (DRVOTO), which is a physiologic finding (i.e., benign and of little clinical significance). This type of flow murmur will wax and wane secondary to tachycardia and volume changes. There is however a significant amount of LV remodeling and fibrosis, which may be indicative of early pathology or simply represent a normal variant. Regardless the left atrial dimension is normal, and there is minimal risk for complication at this time. Serial echocardiography will be necessary to determine progression and clinical relevance in the future.

If needed, the risk for general anesthesia is low, however heart rate stimulating drugs such as atropine, glycopyrrolate or ketamine should be avoided unless medically necessary. Even without



PATIENT

Bijou Mueller

significant pathology, with this degree of remodeling and diastolic stiffening there is a mildly elevated risk for fluid overload in this patient. Judicious IV fluid use is recommended. Additionally, a screening blood pressure is recommended in any older cat prior to general anesthesia.

SPECIES

Feline

Given these findings, no medications are indicated at this time.

BREED

DSH

Recommend recheck echocardiogram in 1 year to assess for progression or development of disease the pre-existing murmur may mask.

SEX

Female Spayed

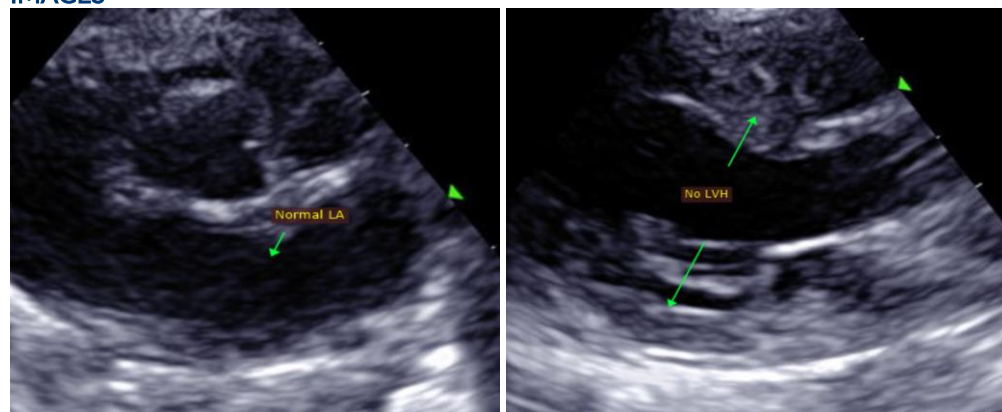
AGE

20 years

WEIGHT

7.4lbs

IMAGES



INTERPRETED BY

Maggie Machen Lamy,
DVM, DACVIM
(Cardiology)

The information and recommendations provided are based on the images presented by the referring veterinarian. No evaluation can be communicated regarding pathology that was not visible in the image/video clips provided.

IMAGING PERFORMED BY

Jessica Miller, RDMS

Thank you for this referral. This report was generated using transcription software, and minor dictation errors may be present. If the clinical or image interpretation does not parallel your findings or if I can be of any further assistance, please contact me.

Maggie Machen Lamy, DVM
Diplomate of the American College of Veterinary Internal Medicine (Cardiology)
info@sonopath.com

HOSPITAL NAME

Animal General on Hudson

REFERRING VET

Dr. Ng

INVOICE

32105

DATE

8/2/23